



Educational tales from Bangor ED...

# Gastroenteritis that wasn't (or, the day the hoofbeats were zebra)



This is the story of a man we'll call Bryn Jones. We are sharing it with you at the request of - and with the involvement of, and contributions from - Bryn's wife Fiona. Only their names have been changed.

Bryn's presentation was unusual, and by sharing it, we hope that one day, a doctor somewhere, will get a head start on realising what is going on with a patient presenting in a similar way, and maybe save their life.

This is our 2nd #FOAMed educational "co-production", albeit with family, not patient, this time, as sadly Bryn did not survive. We hope you find it useful and would welcome your feedback.

## Every Emergency Physician knows about bowel ischaemia...

### volvulus

[vol-vyuh-luh s]

noun, plural  
volvuluses.

Pathology.

1. a torsion, or  
twisting, of the  
intestine, causing  
intestinal obstruction.

After all, this is core knowledge. **Sigmoid volvulus** happens in the elderly (a not-uncommon cause of intestinal obstruction) with **caecal volvulus** a lot rarer, in slightly younger patients. Both present with abdominal pain and bowel obstruction. Then there's **bowel ischaemia**, which we've all seen in elderly patients in AF, with horrendous abdominal pain, desperately unwell, and yet with a soft abdomen. But as for the small bowel? Well, we might recall that neonates with intestinal malrotation can get a **midgut volvulus**.

But for me - and probably many other EM docs - that's about it. So, when Bryn arrived in my ED one evening, I definitely wasn't thinking **small bowel volvulus**, because he just didn't look anything like my mental model of a patient with 40cm of dead bowel. Here are the salient (and much abbreviated) features of Bryn's tale. I hope you find it helpful. - Dr Linda

## Bryn's Tale

Bryn was one of those patients you just like from the outset. He was a gentleman in his mid-50s with no significant PMHx. He'd had watery diarrhoea for a couple of days (although it had stopped a few hours before, since passing a solid stool at lunchtime) with some intermittent abdominal pain that went away after opening his bowels. He felt thirsty, and a bit faint on standing up. He hadn't eaten for two days, but there'd been no vomiting. He mentioned he was burping a lot.

He looked a bit peaky, but was chatting happily about his recent early retirement (the week before, in order to spend more time with family) and rueing the social engagements he'd had to cancel due to being ill. He'd been seen by the out-of-hours GP that afternoon who diagnosed gastroenteritis, but arrived at ED by ambulance a few hours later. The paramedics had found him tachycardic with a postural drop, but 750ml of crystalloid later, and his BP was up and pulse down. His respiratory rate was 18, pain score 4/10, tongue dry, and his abdomen

"generally mildly tender esp central area, but no guarding and no rebound; no AAA palpable; bowel sounds ↑↑".

The bowel sounds were very active: when I first saw Bryn (at 8.30pm, in the back of an ambulance parked outside the ED) I'd made the paramedic & tech have a listen and explained that I thought it was "intestinal hurry", because there wasn't any severe abdominal pain, vomiting or absolute constipation to suggest obstruction. In fact, it even crossed my mind that with another litre of fluid, we might be able to get Bryn home.

By 9pm, we'd found a suitable room inside the ED, and I took another look at him once he was inside the building. Now, under proper lights, I thought he looked "unwell; pale and grey; clammy on sitting up" and I started to get a little bit worried.

I asked for an ECG & bloods, but wrote "History overwhelmingly suggests gastroenteritis, diarrhoea profuse for 48 hours, now dehydrated with postural drop".



At 9.30pm, I looked at Bryn's venous blood gas results with a feeling of absolute horror. After a moment's pause to stop convincing myself they might be spurious (yup, for real) I rapidly revised my working diagnosis to AKI caused by pre-renal renal failure secondary to dehydration.

### 9.25pm - VBG

pH	7.190
pCO <sub>2</sub>	4.7
Na	141
K	4.1
Hct	59.4
HCO <sub>3</sub>	13.1
BE	-13.9
Lac	10.3

I moved Bryn into resus, swung into action stepping up the intensity of treatment & went to re-evaluate him. He actually *looked* much better: sitting up comfortably, chatting, no longer clammy, with his tachycardia resolving as fluids went in. The lactate (10.3) rang alarm bells that I should look for dying tissue... I just didn't know where.

His abdomen was still soft and pain score still only 3/10. I couldn't see his aorta with US due to bowel gas. I had specifically considered the possibility of dead bowel, but specifically dismissed it from my differential diagnosis, writing, "*I do not think ischaemic bowel is likely - not enough pain*".

Around 10pm, I realised that Bryn's respiratory rate - previously 18/min - was pushing 30, and yet he said he didn't feel short of breath. It was Kussmaul's

breathing, and I remember thinking, "surely he can't be getting acidotic that quickly with pre-renal AKI?". And then the blood results came back: urea 9.0, creatinine 208... not the gross pre-renal AKI picture I'd expected. Yet Bryn was clearly getting rapidly more acidotic, and I didn't know why.

Hence, I interrupted the Acute Medicine ward round (my consultant colleague and friend, Chris Subbe was doing a late round in ED) and asked for an immediate second opinion. Chris examined Bryn and noted that his previously-very-active bowel sounds had completely disappeared, providing the vital clue of progressive intra-abdominal pathology. An urgent CT revealed that Bryn had a dilated stomach & fluid in the abdominal cavity. His condition then started to deteriorate very rapidly, and by the time he went to theatre in the early hours of the morning, he required inotropic support.

At laparotomy, our surgical colleague Nik found 40cm of dead bowel caused by a small bowel volvulus. This was resected and Bryn taken to ITU. Sadly, after a stormy 3-week ITU stay and several trips to theatre, Bryn died.

## Reflections from Fiona (Bryn's wife)

*Fiona has been an integral part of the team that created this Medical Education project, from helping us to edit and refine the narrative, to guiding us about what aspects were of particular importance to her. These are her reflections on the contact with medical services that took place on the day Bryn was admitted to hospital:*

"Bryn was so gravely ill, but no alarming symptoms, just dehydration. I understand I could not have done any more for Bryn, although I have a niggly feeling of guilt regarding the GP who saw Bryn earlier that day: I did say that it was the first time ever, in Bryn's 50-plus years, that he'd visited A&E. Should I have emphasized this fact more... would he have been admitted, or sent for a scan?

There is enormous responsibility – and guilt - felt by relatives when things go wrong during a hospital appointment. I'll never be able to explain how much you and this process has helped me overcome that. I feel I'm helping my husband *[by sharing his story]*. I know he would have done this for me, turning every stone to help him and others to understand what happened.

I want everybody to know how well Bryn presented himself on that night: I still recall all our conversations, even on the way to theatre. Joking away, and so grateful to every member of staff, even though he did realize something must be wrong. And that is something that is so difficult to comprehend, that you can chat with your husband (I was trying not to panic) up to quite late in the night, and just half an hour later he was fighting for his life and in septic shock with his organs failing".



# Small Bowel Volvulus: know thy enemy...

- In SBV, a twist in the bowel nips off the venous return (or restricts it sufficiently) so that rising venous pressure eventually restricts/overcomes the ability of arterial pressure to perfuse the gut adequately (or may result in no perfusion at all).
- The twist doesn't necessarily come on in one go: a patient might go for hours (or days) with intermittent vague symptoms as the "proto-volvulus" twists & untwists, leading to symptoms that come and go with intermittent ischaemia of varying degrees (and might even resolve entirely).
- Desiccated, slow-moving bowel contents are a known risk factor
- It is only when the bowel finally infarcts that the symptoms and signs become obvious, fixed and progressive, by which time it is almost too late: once the intestinal barrier has been broken, even if the dead bowel is removed rapidly, you're hoping for a miracle of antibiotics and aggressive ITU care to deal with the aftermath of gut organism influx and cytokine release.
- SBV is very rare and there are no useful diagnostic symptoms, signs, or investigations that can lead to a certain diagnosis prior to the twist becoming fixed - just a high index of suspicion that it may be a 'surgical tummy'. Clues may be very subtle.
- Our patient was younger and fitter than many ED bowel ischaemia patients: he compensated for a very long time, which made reaching a very rare diagnosis even more difficult.

### An anatomical risk factor

Bryn became ill in Spring 2016, but there was possibly a contributory factor that occurred more than half a century before.

The mesentery is formed during week 5 of embryological development, and volvulus is more often seen in patients with a longer-than-normal mesentery.

One of the functions of mesentery is to "hold the bowel in place": if it's too long, it's more likely to twist.

## With the retrospectroscope *Linda Dykes (Consultant EM) ponders...*

Bryn is one of those patients I will never forget. I recall what a lovely couple Bryn and Fiona were. I remember feeling completely at a loss, diagnostically, for the first time in years. I remember feeling utterly bewildered when I heard what the surgeons had found.

I recall *consciously* fighting off some cognitive biases once I realised it wasn't "just" dehydration from diarrhoea, as I tried to methodically form my differential diagnosis list.

But, because I had actively, and thoughtfully - but wrongly - dismissed the diagnosis of ischaemic bowel (because Bryn's presentation was so different to any bowel ischaemia I had seen, read about, or heard

of in the past) it was then impossible for me to find the right answer.

Should I have paid more attention to Bryn telling me he'd been burping a lot? Well, a lot of people burp a lot after swallowing air - I do it when I'm concentrating! Could I have have recognised that, at some point (we don't know exactly when) his "colicky abdominal pain typical of gastroenteritis" probably switched to being due to his bowel twisting and untwisting, until it finally stuck in a twisted position and cut off its own blood supply? Without having small bowel volvulus on my radar (I had simply never heard of it happening to adults) I don't see how I could have known.

I know I did my level best to look after Bryn. But he had a diagnosis that was, for me, an "unknown unknown". Thankfully, I didn't delay in "phoning a friend" (see Chris Subbe's notes on the next page) who was able to look with a fresh pair of eyes and get us back on track.

We hope that by sharing Bryn's story, small bowel volvulus won't be an unknown unknown to you. Maybe one day you'll see a patient with "gastroenteritis" who's sicker than they should be, even if they have minimal abdo pain and aren't vomiting. And on that day, we hope that you'll remember Bryn's story, and consider the possibility of small bowel volvulus in time to save your patient's life.



## Redundancy in safety systems - Dr Chris Subbe (Consultant AM)

When I saw Bryn [two hours after he first presented, when he was much sicker than on his arrival at the ED] I was looking through a different lens to my EM consultant colleague Linda:

- firstly, an experienced colleague had been worried enough to ask for an immediate second opinion;
- secondly, Bryn's raised lactate made my "sepsis" pulse race!

Starting with this different cognitive bias (although, like Linda, I also anchored the problem around "dead tissue") I was looking at Bryn's case afresh and so independently. This approach of using independently working systems - "modular redundancy" - is industry standard for safety-critical processes. "Triple" or even "Quadruple" modular redundancy is used in aviation, nuclear, computer science.


In a [recent study in our hospital](#)\*, we used modular redundancy (if a patient's physiological observations deteriorated, at least two people were informed) to lower the number of in-hospital cardiac arrests by 80% on the two hospital wards trialling the approach.

What is "safety critical" in clinical care?

- abnormal physiology
- "red flag" lab data
- unexplained pain.

Although this approach sadly did not save Bryn's life, asking an independent ("redundant") colleague was a crucial step in reaching the diagnosis.

\*Subbe et al. *Critical Care* (2017) 21:52 DOI 10.1186/s13054-017-1635-z

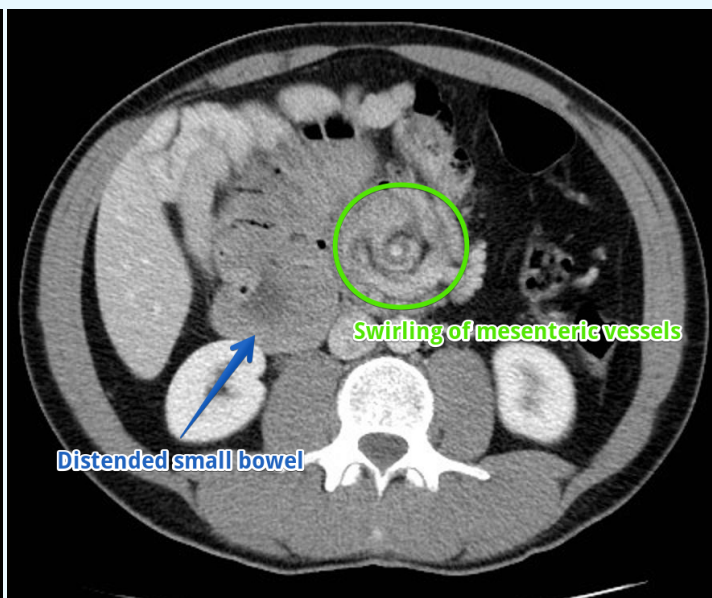
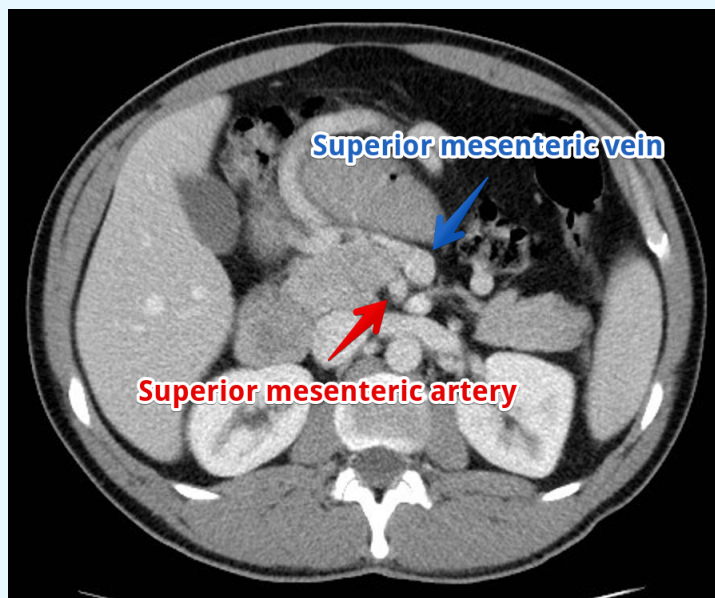


## Small Bowel Volvulus: CT appearance (NB - these aren't Bryn's images)

**LEFT:** normal relationship of the superior mesenteric artery and vein (SMA and SMV) has been reversed. The SMA now lies to the right (right of the patient; left of image as you look at it) and the SMV on the left.

**RIGHT:** The second image shows another CT feature of volvulus of the midgut: swirling of the mesenteric vessels, known as the "whirlpool sign". The small bowel is distended proximal to the twist which acts as a transition point.

Case and CT images courtesy of Dr Maxime St-Amant, [Radiopaedia.org](http://Radiopaedia.org), rID: 18931 and used with permission.





Linda writes: The “co-production” of medical education resources is a relatively new term, and most of us have little experience yet. The “norms” are not yet set. From the point of view of Bangor ED, this is only our second co-production (our first was about spontaneous unstable spinal fractures in Ankylosing Spondylitis) and we are very much still learning. It was almost a year ago - six month's after Bryn's death - that I met with Fiona at her home, to ask if she might consider allowing us to share his story to help raise awareness that small bowel volvulus is a deadly condition that - in Bryn - masqueraded as gastroenteritis until it was too late.

In the intervening months, Fiona and I corresponded on a number of occasions, until we both felt ready to push on and produce the document you are reading now. I asked Fiona how she felt about the process:

**Preparing this educational material has involved you hearing in detail about the thought processes of a doctor who didn't know what was wrong with your late husband. How did you reach this level of mutual trust?**

Mutual trust is something you can't gain/win over overnight, it's a very gradual process. For me it started when one doctor (EM consultant) was so honest with me, and shared every little detail about my husband and was so desperately wanting to help me understand Bryn's case... I started listening.

Because I constantly think about that day when Bryn went to hospital, it was a relief to be able to discuss that day in detail with the very doctor that saw Bryn. And then, once you understand more about the difficult dilemmas that doctors face on a daily basis you can sympathise with them, even when discussing your husband's case. She answered every question/concern I had, no matter how stupid or weird they were, in a very

understandable language: this is so important for people like me with no medical background.

**You'll have learned a lot about Small Bowel Volvulus whilst contributing to the editing process. Did you find that helpful or intrusive?**

It has been difficult at times, because I did not know anything at all about small bowel volvulus, but overall it has helped me. It was similar to a jigsaw: piece by piece, it formed the full picture of a tragic situation, a freak condition where I was helpless.

*“Although I have lost my beautiful husband and best friend, there are some things that will stay with me for ever, and that is the kindness and love shown to Bryn and us, his family. He would be so grateful to the staff for trying their very best to save him”.*

**How did other members of the family react to the plan to tell the tale of their father's death?**

The grieving process is such a difficult time, and still is. My three children supported me in such an amazing manner, therefore I had to respect their wishes: they support this medical education publication, and understood the importance and intentions, but didn't want to use their father's real name or photograph. Hence why we have used pseudonyms for myself and “Bryn”.

**Do you have any advice for teams wishing to work with another bereaved family in a similar way in the future?**

Taking part in this innovative project has been a big deal for myself and Linda, but since working on it, the “what ifs?” in my mind have reduced dramatically. Stick to the same principles: honesty and sincerity. Families will feel very privileged discussing with doctors, giving them the chance to voice their concerns, and feel that somebody wants to hear their story.

### About this “Educational Tales from Bangor ED” production:

- This #FOAMed personal production (independent of our employers) was written by Dr Linda Dykes (the Consultant in EM who didn't know what was wrong with Bryn) and Bryn's wife Fiona, along with Dr Chris Subbe (Consultant in AM, @csubbe) & Mr Nik Abdullah (Consultant Surgeon). Please note that Bryn and Fiona are pseudonyms.
- Additional contributions by Dr Vikas Shah (Consultant Radiologist, @DrVikasShah), and Professor Ewen Sim.
- Concept devised by Dr Linda Dykes; editing by Linda and Fiona; design by Linda.
- We'd love your feedback: please contact Linda on Twitter @mmbangor or email Linda.Dykes@wales.nhs.uk
- You can find more of our educational “Bog Blogs” (they're usually single-page productions!) at [www.scribd.com/BangorED](http://www.scribd.com/BangorED)
- For other information about Bangor ED, please visit our unofficial website at [www.mountainmedicine.co.uk](http://www.mountainmedicine.co.uk)